Flexible Ureterorenoscopy for the Treatment of Kidney Stone Within Pelvic Ectopic Kidney

Omer Faruk Bozkurt, Abdulkadir Tepeler, Brian Sninsky, Ekrem Ozyuvali, Tevfik Ziypak, Gokhan Atis, Mansur Daggulli, Berkan Resorlu, Turhan Caskurlu, and Ali Unsal

OBJECTIVE To present the outcomes of flexible ureterorenoscopy (F-URS) and laser lithotripsy for the treatment of calculi within pelvic ectopic kidney (PEK).

PATIENTS AND METHODS We retrospectively reviewed the medical records of 26 patients with calculi in PEK treated with F-URS in 5 referral hospitals between 2010 and 2013. Patient demographics and stone characteristics (age, sex, body mass index, stone size, location, history of shock wave lithotripsy or kidney surgery), and perioperative measures (duration of operation, fluoroscopic imaging, and hospitalization and success and complication rates) were reviewed.

RESULTS A total of 26 patients with mean age of 41.1 ± 15.8 years (7-72 years) were included in the study. The mean stone size was 17.0 ± 5.1 mm (10-28 mm). The mean procedure and fluoroscopy times were calculated as 52.1 ± 27.7 minutes (30-120 minutes) and 54.8 ± 48.9 seconds (10-180 seconds), respectively. The mean length of hospital stay was 2.7 ± 1.8 days (1-9 days). Treatment was deemed successful in 22 patients (84.6%). Ureteroscopy failed in 4 patients (15.4%) due to impaired passage of fragments (n = 3) or inability to reach the stone secondary to the location in an isolated lower calyx (n = 1). Minor postoperative complications were observed in 5 patients (19.2%; persistent hematuria [n = 1], fever [n = 1], renal colic [n = 2], and urinary tract infection [n = 1]). No severe complications or mortality occurred.

CONCLUSION Our results suggest that F-URS is a safe and effective minimally invasive treatment modality for small- and medium-sized stones in PEK. UROLOGY ■: ■–■, 2014. © 2014 Elsevier Inc.

Congenital anomalies of the urinary tract present challenges to the treatment of urolithiasis. Minimally invasive treatment methods become more difficult in patients with renal abnormalities such as horseshoe kidney, ectopic kidney, or malrotated kidney.[1,2]

Ectopic kidney results from failure of the kidney to ascend to the normal anatomic location in the renal fossa. Common locations for ectopic kidney are pelvic, iliac, abdominal, thoracic, and contralateral. The pelvic ectopic kidney (PEK) is located in the pelvic fossa, anterior to the bladder and below the aortic bifurcation. The accompanying vasculature and rotation abnormalities complicate treatment modalities in these cases.

Shockwave lithotripsy for calculi within PEK is associated with lower success rates secondary to impaired stone clearance and problems with localization.[1-3] Although percutaneous nephrolithotomy (PNL) has higher stone-free rates compared with those of other modalities, it is more technically challenging because of the abnormal renal anatomy.[1,2,4,5] Furthermore, it requires ultrasonography (US) or laparoscopy-guided percutaneous renal access in the supine position.

With the introduction of new-generation flexible ureteroscopes, with a higher degree of flexion and deflection capabilities combined with laser lithotripsy, flexible ureterorenoscopy (F-URS) has been used as an alternative treatment method in this unique group of patients. However, there are only limited studies with small patient groups in the literature.[6,7]

In this study, we aim to present the outcomes of F-URS for the treatment of calculi within PEK. To the best of our knowledge, this study includes the largest series of patients thus far with PEK.

Financial Disclosure: *The authors declare that there are no relevant financial interests.*

From the Department of Urology, Kecioren Teaching and Research Hospital, Ankara, Turkey; the Department of Urology, Faculty of Medicine, Bezmialem Vakif University, Istanbul, Turkey; the Department of Urology, School of Medicine and Public Health, University of Wisconsin, Madison, WI; the Department of Urology, Faculty of Medicine, Ataturk University, Erzurum, Turkey; the Department of Urology, Faculty of Medicine, Medeniyet University, Istanbul, Turkey; the Department of Urology, Faculty of Medicine, Dicle University, Diyarbakir, Turkey; and the Department of Urology, Faculty of Medicine, Gazi University, Ankara, Turkey

Address correspondence to: Abdulkadir Tepeler, M.D., Department of Urology, Faculty of Medicine, Bezmialem Universitesi Hastanesi, Adnan Menderes Bulvari, Vatan Caddesi, 34093, Fatih, Istanbul, Turkey. E-mail: akadirtepeler@yahoo.com

Submitted: March 19, 2014, accepted (with revisions): July 22, 2014

http://dx.doi.org/10.1016/j.urology.2014.07.041
0090-4295/14

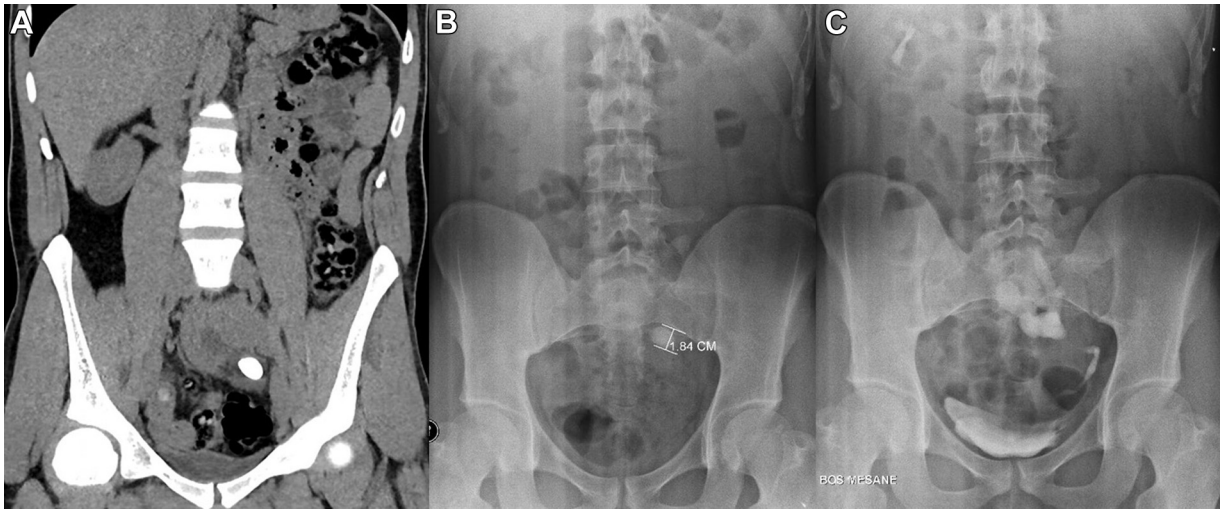

Figure 1. The computed tomography **(A)** and intravenous urography **(B** and **C)** images of a patient with 1.84-cm calculi within left-sided pelvic ectopic kidney.

PATIENTS AND METHODS

We retrospectively reviewed the medical charts of 26 patients with calculi located in PEK who were treated with F-URS and laser lithotripsy in 5 referral hospitals between 2010 and 2013. Patient demographics and stone characteristics (age, sex, body mass index, stone size, location, history of shock wave lithotripsy [SWL], or kidney surgery), and perioperative measures (duration of operation, fluoroscopic imaging, and hospitalization and success and complication rates) were reviewed.

All patients were routinely assessed with laboratory tests including serum biochemistry, complete blood test, coagulation profile, urinalysis, and urine culture. Radiologic evaluation was used to determine stone size, and included computed tomography and/or intravenous urography completed preoperatively (Fig. 1). Patients with a positive urine culture were treated with appropriate antibiotics.

Operative Technique

Surgeries were performed by experienced endourologists in all 5 centers. The procedure was performed in supine position under general anesthesia in the lithotomy position. After insertion of a guidewire into the ureteral lumen, retrograde ureteropyelography was done through a ureteral catheter to outline the abnormal anatomy. A secondary safety guidewire was inserted and a flexible ureteroscope (Flex-X2; Karl Storz, Tuttlingen, Germany) was advanced over the guidewire under fluoroscopic imaging (Fig. 2). A ureteral access sheath was not used because of the short and tortuous ureter, and an abnormal ureteral route. The stone was visualized and fragmented with the dusting technique using a 200-μm Ho:YAG laser fiber with the settings of 0.8 J and 10 Hz. In the event, the stones could not be targeted; they were relocated using the basket catheter. A ureteral J stent was inserted in patients with stones ≥2 cm, narrow and tortuous ureter, and large residual fragments related to incomplete fragmentation.

Follow-up

Patients were evaluated with plain film, and those without complications were discharged on postoperative day 1. Postoperative complications were graded using the Clavien-Dindo Classification system.[8] Final stone clearance was determined by computed tomography at 4-week postoperative follow-up. Success was defined as stone-free or residual fragments <2 mm.

RESULTS

The demographic, perioperative characteristics, operative, and postoperative outcomes are summarized in Table 1.

Demographics and Stone Characteristics

A total of 26 patients with the mean age of 41.1 ± 15.8 years (7-72 years) were included in the study. The mean body mass index was 26.6 ± 6.1 kg/m^2 (20.6-31.5 kg/m^2). The mean stone size was 17.03 ± 5.1 mm (10-28 mm). Of the 26 patients, 9 had previously failed SWL therapy within 6 months. One of the patients had a previous open renal surgery for stone disease.

Perioperative Measures and Outcomes

The mean procedure and fluoroscopy times were calculated as 52.1 ± 27.7 minutes (30-120 minutes) and 54.8 ± 48.9 seconds (10-180 seconds), respectively. A ureteral J stent was inserted in 12 (46.2%) patients at the end of the surgery. The mean hospital stay was 2.7 ± 1.8 days (1-9 days). Treatment was deemed successful in 22 patients (84.7%). Although 17 patients (65.3%) were completely stone free, 5 patients (19.2%) had residual fragments <2 mm. On the other hand procedure failed in 4 patients (15.4%) due to impaired passage of fragments (n = 3), or inability to reach the stone secondary to location in an isolated lower calyx (n = 1). These patients had stones ≥2 cm located in the lower calyx (n = 2) and pelvis (n = 2).

Postoperative complications were observed in 5 (19.2%) patients. Persistent hematuria (Clavien grade 1 complication) was observed in 1 patient and resolved spontaneously during follow-up. Postoperative fever (Clavien grade 1 complication) was observed in a patient and resolved with no additional antibiotic therapy. Ureteral J stent placement was required in 2 patients with

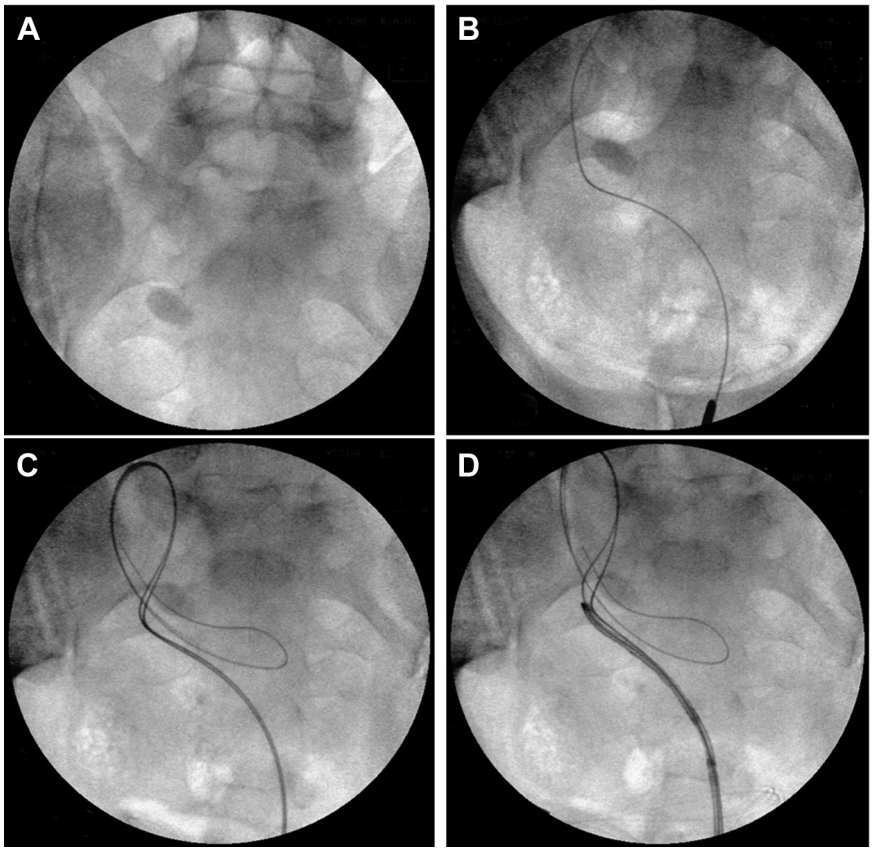

Figure 2. The placement of guidewires to a right-sided pelvic ectopic kidney **(A**, **B**, and **C)**, flexible ureterorenoscope over the guidewire and abnormal course **(D)** of the ureter.

severe renal colic that did not resolve with medical treatment (Clavien grade 3a complication). Finally, a urinary tract infection was managed with appropriate antimicrobial therapy in 1 patient (Clavien grade 2 complication). No severe complications occurred.

COMMENT

PEK is an abnormality resulting from failure of the kidney to ascend properly during embryologic development. It is reported that the incidence of pelvic kidney ranges from 1 in 500 to 3000.[1,6,9,10] Patients with PEK are more likely to develop urolithiasis compared with the normal population.[11] This is linked to impaired drainage of the kidney due to altered anatomy, as well as metabolic reasons.

Traditionally, open surgery was performed for the treatment of urolithiasis in patients with PEKs. After the introduction of SWL and improved targeting and experience, it has also been used in this unique subset of patients. Success rates for SWL on renal calculi in PEK range between 25% and 91.7%,[3,10,12-14] with the largest series reporting a rate of 82%.[10] The mean number of sessions per patient was reported as 1.2. In this study, steinstrasse occurred in 2 (14%) patients, requiring additional SWL (n = 1), or URS (n = 1). Tunc et al[3] used SWL in 14 PEKs, and reported a stone-free rate of 57.2%. An additional 35.7% of patients had sufficient stone fragmentation, but failed clearance. In this study, the authors argue that SWL is an effective treatment modality for renal stone <2 cm in patients with anatomic abnormalities of the urinary tract. In our current series, the mean stone size was 15.6 mm in the 9 patients who had failed SWL. SWL was not used due to localization problems in the other patients.

Table 1. The demographics of the patients, procedure-related values, and postoperative outcomes are summarized

N	26
Mean age (y)	41.1 ± 15.8 (7-72)
Male/Female	19/7
Body mass index (kg/m^2)	26.6 ± 2.6 (20.58-31.5)
Stone size (mm)	17.0 ± 5.1 (10-28)
Stone location	
Pelvis	14
Lower calyx	7
Multiple calyx	5
Previous treatment modality	
SWL	9
Open surgery	1
Operation time (min)	52.1 ± 27.7 (30-120)
Fluoroscopy time (s)	54.8 ± 48.9 (10-180)
Hospitalization (d)	2.7 ± 1.8 (1-9)
Success rate (%)	22/26 (84.7)
Complication rate (%)	5/26 (19.2)

SWL, shock wave lithotripsy.

The pelvic bony structures that prevent stone localization and targeting are the main problems in using SWL in patients with PEK. To overcome these limitations,

Table 2. Results of the studies for the treatment of calculi within pelvic ectopic kidney with RIRS

Study	No. of Patients	Mean Age (y)	Stone Size	Operation Time (min)	Fluoroscopy Time (s)	Hospitalization (d)	Success Rate (%)	Complication Rate (%)
Fayyad et al[6]	4	44	NA (>30 mm)	120	NA	NA (2-3)	75	0
Weizer et al[7]	4	NA	NA	NA	NA	NA	75	NA
Binbay et al[18]	24	40.7	147.5 mm^2	68	NA	NA	70.8	NA
Present study	26	41.1	17 mm	52.1	54.8	2.7	84.7	19.2

NA, not available; RIRS, retrograde intrarenal surgery.

prone positioning of the patient or US guidance is generally preferred. The other factor that may decrease the success of SWL is impaired drainage of the kidney. High-ureteral insertion, malrotation and anteriorly placed pelvis, and obstruction related to the abnormal vasculature, are also regarded as reasons for impaired drainage and hydronephrosis in pelvic kidneys. To rule out ureteropelvic junction obstruction, intravenous urography or diuretic renogram is recommended in patients with anomalous kidneys. In the present study, contrast imaging was used in 6 patients with moderate-to-severe hydronephrosis, though was not detected in any of the patients.

The other treatment option for stones in PEK is percutaneous nephrolithotomy (PNL). Although PNL is regarded as the primary treatment option with high success and acceptable complication rate for large renal calculi, the procedure for PEK is more technically challenging, even for experienced urologists. The technical problem in these cases is obtaining a proper and safe access to the kidney located in the pelvic fossa, surrounded by pelvic bone and visceral organs. There are 2 primary methods described in the literature for gaining access, and include US- vs laparoscopy-guided percutaneous renal access. US-guided PNL for PEK was first reported by Desai and Jasani[4] The procedure was performed in supine oblique position, with the selection of the calyx for access by retrograde pyelography under C-arm fluoroscopy. In their technique, they avoided bowel injury by displacing bowel loops away by the pressure applied with the transducer probe. In addition, the PEK was shifted closer to the abdominal wall by contralateral abdominal pressure. They used their technique in 16 patients with PEK during a 16-year period.[15] In this series, 5 patients were treated with a 2-staged PNL procedure, and they achieved stone-free status in all patients with a mean length of hospital stay of 4.7 days. However, it is important to note that 18% of patients experienced severe complications, including bowel injury, hematoma, and postoperative ileus. The authors did not expand on the management of these complications in this brief abstract.

The use of laparoscopy for transperitoneal PNL was initially described by Toth et al.[16] In this technique, a safe transperitoneal renal access was obtained by mobilization of bowel loops over the PEK. Laparoscopic suturing of the nephrotomy may eliminate requirement for a nephrostomy tube, reduce hospital stay, and decrease the risk of urine leakage into the abdominal cavity.[5] Although experts[5,15,16] conclude that PNL has a higher stone-free rate for large and complex renal calculi in PEK, requirement for surgical experience, prolonged hospital stay, and risk of severe complications are the main drawbacks. In the present study, all patients had small-to-moderate—sized renal calculi, and PNL was not considered as a primary treatment option in any case.

With the advancements in F-URS and the introduction of laser lithotripsy, the indications for RIRS have expanded in recent years. Today, RIRS is recommended as the treatment of choice for SWL resistant small-to-medium sized renal stones. This accumulation of experience has led some endourologists to use F-URS for calculi in anomalous kidneys.[6,7,17]

Weizer et al[7] published their F-URS experience in anomalous kidneys that included 4 cases of PEK, and 4 cases of horseshoe kidney. They accomplished stone-free status in 3 of 4 (75%) patients with PEK. However, in this study the authors did not present demographic or operative data specifically for patients with PEK. In a study by Fayad,[6] the authors treated 4 patients with renal calculi >3 cm within PEK using a 9F rigid ureteroscope. According to their study, open surgery was required in 1 patient with ureteropelvic junction obstruction accompanying PEK. They accomplished stone-free status in 3 of 4 patients (75%), with no reported postoperative complications. Binbay et al[18] evaluated the outcomes of F-URS in patients with PEK that included 17 patients with a mean stone area of 147.5 mm^2. The stone-free rate after a single session of URS was reported as 70.8%. No major complications were reported by the authors. In our present study, the mean stone size was 17.0 mm, and 22 of 26 cases (84.7%) were a stone-free rate after a single URS session. Although minor complications were observed in 5 (19.2%) cases, none were severe. Table 2 summarizes the studies focused on F-URS for renal calculi within PEK.

Anatomic variations, stone size, and location are important factors affecting the success of F-URS. PEK is a unique condition involving multiple abnormalities challenging the F-URS procedure. A short and tortuous ureter with an abnormal course related to low and malrotated PEK is the main reason restricting the use of access sheaths. Insertion of ureteral access sheath may be traumatic and can lead to serious ureteral injury, so we did not use this instrument in these patients. We advanced the scope over guidewire to the collecting system.

Despite to the higher degree of flexion and deflection capability of new generation ureterorenoscopes, high-ureteral insertion and lower caliceal localization of stone

within PEK are other factors challenging the procedure. Although we used baskets to re-localize the stone, we failed to reach the stone in most of these cases due to step infundibulopelvic angle. The other reason for the failure of the procedure was an incomplete clearance of the stone fragments due to anatomic alterations.

Although the F-URS procedure is done in outpatient fashion in some countries especially in US, we routinely discharge patients on postoperative day 1 after the procedure in our country. We think this is one of the reasons related to prolonged hospitalization time in the present series. The other reason for the prolonged hospitalization period is the treatment process of the complications. Fortunately, we had a relatively low rate of complication. But prolonged hospitalization was needed to overcome the complications. For example, a patient with urinary tract infection was managed with antibiotherapy and discharged on postoperative ninth day.

The retrospective nature and lack of comparison with other treatment modalities are the main limitations of the study. However, we believe that this study, the largest case series to date, contributes to the literature in terms of selection of optimal treatment modality in patients with PEK. Further prospective comparative studies are warranted.

CONCLUSION

The results of our study suggest that F-URS is a safe and effective minimally invasive treatment modality for small- and medium-sized renal calculi in patients with PEK.

References

1. Stein RJ, Desai MM. Management of urolithiasis in the congenitally abnormal kidney (horseshoe and ectopic). *Curr Opin Urol*. 2007;17:125-131.
2. Ganpule AP, Desai MR. Urolithiasis in kidneys with abnormal lie, rotation or form. *Curr Opin Urol*. 2011;21:145-153.
3. Tunc L, Tokgoz H, Tan MO, et al. Stones in anomalous kidneys: results of treatment by shock wave lithotripsy in 150 patients. *Int J Urol*. 2004;11:831-836.
4. Desai MR, Jasani A. Percutaneous nephrolithotripsy in ectopic kidneys. *J Endourol*. 2000;14:289-292.
5. Matlaga BR, Kim SC, Watkins SL, et al. Percutaneous nephrolithotomy for ectopic kidneys: over, around, or through. *Urology*. 2006;67:513-517.
6. Fayad AS. Retrograde holmium:YAG laser disintegration of stones in pelvic ectopic kidneys: would it minimize the risk of surgery? *J Endourol*. 2008;22:919-922.
7. Weizer AZ, Springhart WP, Ekeruo WO, et al. Ureteroscopic management of renal calculi in anomalous kidneys. *Urology*. 2005;65:265-269.
8. Dindo D, Demartines N, Clavien PA. Classification of surgical complications: a new proposal with evaluation in a cohort of 6336 patients and results of a survey. *Ann Surg*. 2004;240:205-213.
9. Abeshouse BS, Bhisitkul I. Crossed renal ectopia with and without fusion. *Urol Int*. 1959;9:63-91.
10. Talic RF. Extracorporeal shock-wave lithotripsy monotherapy in renal pelvic ectopia. *Urology*. 1996;48:857-861.
11. Bauer SB. Anomalies of the upper urinary tract. In: Walsh PC, ed. *Campbell's Urology*. 8th ed. Philadelphia: W.B. Saunders; 2002.
12. Kupeli B, Isen K, Biri H, et al. Extracorporeal shockwave lithotripsy in anomalous kidneys. *J Endourol*. 1999;13:349-352.
13. Rigatti P, Montorsi F, Guazzoni G, et al. Multimodal therapy for stones in pelvic kidneys. *Urol Int*. 1991;46:29-34.
14. Baltaci S, Sarica K, Ozdiler E, et al. Extracorporeal shockwave lithotripsy in anomalous kidneys. *J Endourol*. 1994;8:179-181.
15. Gupta RC, Desai MR, Anil R, et al. Role of percutaneous nephrolithotomy in pelvic ectopic kidneys—17 years experience [abstract]. *J Endourol*. 2006;20(Suppl 1):A22.
16. Toth C, Holman E, Pasztor I, et al. Laparoscopically controlled and assisted percutaneous transperitoneal nephrolithotomy in a pelvic dystopic kidney. *J Endourol*. 1993;7:303-305.
17. Molimard B, Al-Qahtani S, Lakmichi A, et al. Flexible ureterorenoscopy with holmium laser in horseshoe kidneys. *Urology*. 2010;76:1334-1347.
18. Binbay M, Skolarikos A, Unsal A, et al. Outcomes of retrograde intrarenal lithotripsy in pelvic kidneys. *J Endourology*. 2012;20(Suppl):A154.