CASE REPORT

COMPLETE DIPHALLUS IN A 14-YEAR-OLD BOY

Abdulkadir Tepeler, Mert Ali Karadağ, Ünsal Özkuvancı, Erhan Sarı, Yalçın Berberoğlu, Ahmet Yaser Müslümanoğlu

Haseki Eğitim ve Araştırma Hastanesi, Üroloji, İstanbul, Türkiye

ABSTRACT

We herein present an unusual case of 14-year-old boy with complete diphallus and bifid scrotum. He was not aware of his extragenital abnormality until he was examined by a surgeon before circumsion. During surgery, the hypoplastic penis was resected and a single scrotum was constructed by removing the band of skin separating the compartments. The rugose skin was then joined, giving scrotal continuity.

Keywords: Diphallus, urethra, bifid scrotum

14 YAŞINDAKİ ERKEK ÇOCUĞUNDA KOMPLET DİFALLUS

ÖZET

14 yaşında komplet difalluslu ve bifid skrotumlu olgu sunacağız. Hasta ekstragenital anomalisinden, sünnet oluncaya kadar ve bir cerrah tarafından görülmeden önce farkında değildi. Ameliyatta, kompartmanları ayıran cilt bandı kaldırılarak skrotum rekonstrükte edildi ve hipoplastik penis rezeke edildi. Geriye kalan deri birleştirilerek, skrotal devamlılık sağlandı.

Anahtar Kelimeler: Difallus, üretra, bifid skrotum

INTRODUCTION

Diphallus, or duplication of the penis or clitoris is a rare anomaly that occurs once in every 5 million live births[1]. This was the second diphallus case at our institution[2].

The extent of duplication and the number of accompanying anomalies vary greatly from a double glans arising from a common shaft to complete duplication of the phallus accompanied by multiple anomalies such as ectopic scrotum, prepenile scrotum, bifid scrotum, bladder exstrophy, wide symphysis and imperforate anus. We herein discuss a diphallic boy with bifid scrotum.

CASE REPORT

A 14-year-old male was referred from a state hospital to our institute because of abnormal genitalia. He was not aware of abnormal genitalia because the hypoplastic ventral glans was covered by its prepusium until examined by a surgeon before circumsion. The birth history was normal. The mother and father were healthy. The family history was significant in that a paternal first cousin had hypospadias.

Examination of genitalia revealed a well–formed penis with normally located and functioning urethra and an unseperated accessory smaller ventral penis and a rotated glans with a blind depression at its tip (Figs 1-2). There were two penile shafts located one above the other with two corpora cavernosa. Normal erection of each fallus was observed. The skrotum was bifid and each compartment contained a testicle. Abdominal and other physical examination were normal. The blood analyses were within normal ranges; ultrasonography showed bilateral normal kidneys. Voiding-cystourethrography

İletişim Bilgileri:
Abdulkadir Tepeler, M.D.
Haseki Eğitim ve Araştırma Hastanesi, Üroloji, İstanbul, Türkiye
e-mail: akadirtepeler@yahoo.com

Marmara Medical Journal 2007;20(3);190-192

revealed a normal single bladder and urethra and no vesicoureteric reflux.

A vertical incision over the raphe was used to expose the accessory penis. Then it was liberated by a circumferential incision and dissected up into the pelvis. This hypoplastic phallus was then excised and the associated portion of the ventral penis shaft was closed in layers. A single scrotum was constructed by removing the band of skin separating the compartments. The rugose skin was then joined, giving scrotal continuity. The postoperative period was uneventful (Figure 3).

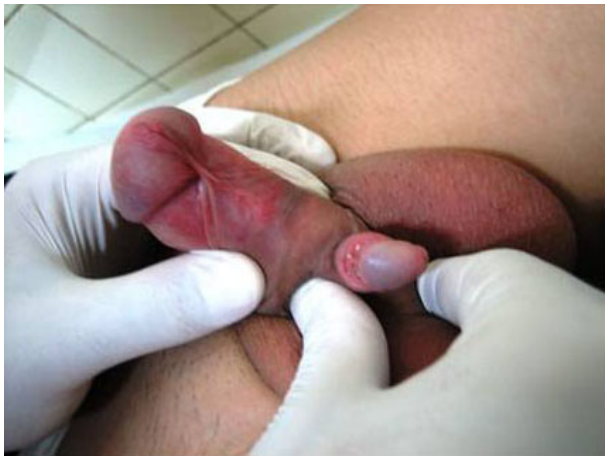

Figure 1: Dorsal well-formed penis and an unseperated accessory smaller ventral penis are seen.

Figure 2: Lateral vision of diphallus

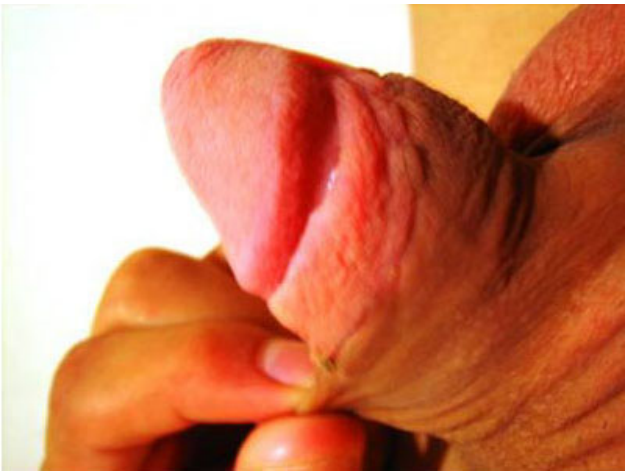

Figure 3: Postoperatively a well formed single penis

DISCUSSION

Diphallus is a rare congenital anomaly occuring once in 5 million live births. The first case was reported in 1609. Neugebauer in 1898, and Nesbit and Bromme in 1933 reviewed cases in the literature[3-6] Diphallus has been classified in different ways, such as glandular, bifid, concealed, complete, hemidiphallus and triple penis[7,8] . Scheneider classified diphalluses in three groups; diphallia of glans alone, bifid diphallia, complete diphallia. Villanova and Raventos have added a fourth category: pseudodiphallia[8,9].

The urethra shows a range of variations, ranging from functioning double urethras to complete absence of urethra in each penis. The majority has a single corpus cavernosum in each phallus. The meatus may be normal, epispadic, or hypospadiac, and the scrotum may be normal or bifid. Associated congenital anomalies are present in the majority of the cases. Bladder, urethra, scrotum, uterus and vaginal duplications, bifid clitoris, anterior ectopic anus, colon, rectum and terminal ileum duplications, mental retardation, spinal anomalies, anal atresia, 11 pairs of costae, renal maldescensus, diplopodia of the left foot, intestinal malrotation, umbilical hernia, ectopic bowel segment have been documented in the literature[7,10].

Multiple embryological explanations for diphallus exist and have been summarized by Wilson and Hallowell[3,8]. Almost all authors

are in consensus that the anomaly is due to a defect of fusion of the genital tubercle. Hallowell et al. have suggested that it results from the failure of fusion of mesodermal bands or presentation of the oppurtunity of mesoderm to surround two urethral anlage[3].

Treatment of diphallus usually includes excision of the duplicated penile structure and its urethra. Therefore, all the patients with diphallia have to be examined carefully because of the high incidence of other systemic anomalies[3].

REFERENCES

1. Viswanatha RT, Chandrasekharam V. Diphallus with duplications of cloacal derivatives. J Urol 1980; 124: 555-558
2. Mutlu N, Baykal M, Merder E, Culha M, Canbazoğlu N. Diphallus with urethral duplication. Int Urol and Neph 1999; 31(2): 253-255.
3. Hallowell JG., Witherington R., Ballagas AJ. Embryologic considerations of diphallus and associated anomalies. J Urol 1977; 117: 728-732.
4. Neugebauer FL. 37 Fälle von Verdoppelung der äusseren Geschlechtsteile. Monatschr F Geburtsch U Gynäk. 1898; 7: 550-555.
5. Neugebauer FL. 37 Fälle von Verdoppelung der äusseren Geschlechtsteile. Monatschr F Geburtsch U Gynäk. 1898; 7: 645-648.
6. Nesbit RM, Bromme W. Double penis and double bladder with report of case. Am J Roentgen 1933; 30: 497.
7. Ravi K, Madan MS. Complete duplication of bladder, urethra and external genitalia. J Urol 1987; 137: 1243-1245.
8. Wilson JSP. Horton C (eds). Diphallus plastic and reconstructive surgery of genital area 1973; 1888-1891.
9. Vilanova X, Raventos A. Pseudodiphallia-a rare anomaly. J Urol. 1954; 71: 338-346.
10. Azmy AF. Complete duplication of the hindgut and lower urinary tract with diphallus. J Pediatr Surg. 1990; 25: 647-649.