JOURNAL OF ENDOUROLOGY
Volume 22, Number 2, February 2008

DOI: 10.1089/end.2006.0445

Is Routine Radiological Surveillance Mandatory After Uncomplicated Ureteroscopic Stone Removal?

MERT ALI KARADAG, AHMET TEFEKLI, M.D., FATIH ALTUNRENDE, ABDULKADIR TEPELER, MURAT BAYKAL, and AHMET YASER MUSLUMANOGLU

ABSTRACT

***Purpose*: Stricture formation and obstruction are rare but significant complications after ureteroscopy (URS), and there are controversial studies regarding follow-up. Our study sought to determine the appropriate follow-up for patients without complications.**

***Patients and Methods*: A total of 323 patients were treated with URS for removal of ureteric stones, and their charts were retrospectively reviewed. A semirigid ureteroscope was used in all patients, and stone disintegration was accomplished with a pneumatic lithotriptor. Postoperative evaluation included plain abdominal radiograph of the kidneys, ureters, and bladder (KUB) on day 1, intravenous urography (IVU) and/or ultrasonography at postoperative month 3 and annually thereafter in all patients. A KUB radiograph was also obtained on postoperative day (POD) 10 in patients with residual fragments.**

***Results*: Complete records of 268 patients were available. The overall success rate was 95.5%. The KUB radiograph on POD 1 revealed complete stone removal in 217 (80.9%) patients, while residual fragments were seen in 40 (14.9%) patients, who were reevaluated on POD 10. Evaluation on POD 10 showed residual fragments in 15 patients, and URS was again performed in eight patients. Perioperative minor complications were observed in 18 (6.7%) patients. IVU performed in the third postoperative month showed stricture formation in two (0.7%) patients and silent obstruction in one (0.3%). No stricture formation was observed in asymptomatic patients after uncomplicated complete stone removal. After a mean follow-up of 27.4 ± 13.7 (range 12–58) months, annual radiologic studies did not show any additional complications.**

***Conclusions*: Our results indicate that radiologic surveillance for stricture formation and obstruction is not mandatory after complete stone removal with uncomplicated URS.**

INTRODUCTION

URETEROSCOPY (URS) has become a valuable aid in both diagnosis and management of urinary tract pathologic findings. The indications for URS include management of calculi and evaluation of hematuria and filling defects.[1–4] Introduction of smaller ureteroscopes, graspers, and baskets and safer intracorporeal lithotriptors has reduced the complication rates.[5,6] Although rarely encountered, stricture formation and obstruction are significant complications after URS stone removal. Because ureteral obstruction or stricture formation after URS may have a negative impact on renal function, many urologists include routine radiologic imaging in postoperative monitoring.[6]

Routine imaging for follow-up has recently been questioned, however, because of the low complication and high success rates of URS stone removal. Studies regarding follow-up after this procedure are controversial.[7–10]

In the present study, we assessed long-term complications of URS stone removal in a cohort of patients with long-term radiologic follow-up. We tried to determine the appropriate monitoring schedule and procedures for patients without complications.

PATIENTS AND METHODS

A total of 323 patients underwent URS for removal of ureteric stones between June 2001 and November 2005 at our

Department of Urology, Haseki Teaching and Research Hospital, Istanbul, Turkey.

institution. Data were collected prospectively, and charts were retrospectively reviewed for clinical and radiologic outcome. Patients in whom urothelial carcinoma (n = 4) and ureteropelvic junction obstruction (n = 13) were detected were excluded from the study. We also excluded 48 patients for whom no postoperative radiographic studies were available. Patients with coexisting kidney stones were not enrolled in the study.

Complete records of 268 patients were available and provided the data for the study. There were 149 men and 119 women. Their mean age was 43.3 ± 12.5 (range 14–75) years. All patients were preoperatively evaluated with routine serum biochemical analyses, plain abdominal radiography (kidneys, ureters, bladder [KUB] view), intravenous urography (IVU), and renal ultrasonography. Renal scintigraphy and CT were obtained in selected patients. There was a history of open surgery in 27 (10%) patients, URS stone removal in 22 (8.2%) patients, and extracorporeal shock wave lithotripsy (SWL) in 48 (17.9%) patients. Severe obstruction secondary to calculus was found in 144 (53.7%) patients, and 26 (9.7%) had Double-J ureteral stents.

Stone size was measured by the largest cross section on the KUB radiograph in patients with radio-opaque stones (n = 251), and by noncontrast spiral CT in patients with radiolucent stones (n = 17). The mean stone size was 1.7 ± 0.6 (range 0.8 to 3.0) cm. The location of stones was the distal ureter in 198 (73.9%) patients, midureter in 40 (14.9%) patients, and proximal ureter in 34 (12.7%) patients. Multiple ureteral stones were present in four patients.

All patients underwent URS with either an 8F or 10F semirigid ureteroscope (Karl Storz, Tuttlingen, Germany). Stone disintegration was accomplished with a pneumatic lithotriptor (Vibrolith, ELMED, Ankara, Turkey). In every case, an effort was made to extract all fragments using basket catheters. In selected patients, Stone Cone® was used or stones were fragmented after being grasped within a basket catheter. In those patients with proximal migration of small fragments, ureteral stents were placed to allow fragments to pass over time. In 19 (7.1%) patients, balloon dilatation of the ipsilateral orifice was performed. Indications for postoperative stenting were ureteral edema secondary to an impacted calculus, iatrogenic ureteral trauma (laceration, perforation), or a significant residual stone burden. The operating consultant determined the need for stent placement.

Postoperative evaluation included a KUB radiograph on day 1 in all patients. A KUB radiograph was also obtained on postoperative day (POD) 10 in patients with residual fragments. URS was again performed when indicated. All patients were then evaluated with IVU and/or ultrasonography in the third postoperative month. Thereafter, all patients underwent annual radiologic surveillance.

No obstruction was designated when the collecting system had no delay in function and no upper tract dilation.[7] Mild to moderate obstruction indicated a delay in the excretion of contrast and mild to moderate hydronephrosis. Obstruction was termed severe when patients had moderate to severe hydronephrosis, delayed excretion, and when contrast did not pass beyond the point of obstruction on IVU evaluation. In patients in whom the use of contrast agents was contraindicated, obstruction was denoted by significant hydronephrosis and/or marked ureteral dilation on CT evaluation. The profile of follow-up, radiologic evaluation, and outcome is displayed in Fig. 1.

Postoperative parameters recorded included evidence of obstruction on postoperative radiologic imaging, cause of obstruction (i.e., residual stone or stricture formation), and concurrent pain. Patients were considered to have "silent obstruction" when there was evidence of obstruction on postoperative imaging without concurrent pain.[7]

RESULTS

Perioperative findings

Stones were disintegrated completely in 182 (67.9%) patients and partially in 75 (27.9%) patients. No stone disintegration was accomplished perioperatively in 11 (4.1%) patients; these patients were referred for open surgery (Fig. 1). In 249 (92.9%) patients, stones were fragmented with a pneumatic lithotriptor, while basket catheters were used in 118 (44.1%) patients. There was no case of ureteral avulsion or severe perforation. Perioperative complications were minor mucosal laceration in 12 (4.4%) patients, proximal migration of fragments in 19 (7.0%) patients, minor ureteral perforation in one (0.4%) patient, and migration of the Double-J ureteral stent in three (1.1%) patients.

A Double-J ureteral stent was placed in 28 (10.9%) patients for 3 to 4 weeks. In 120 (44.8%) patients, a ureteral catheter was placed for one night, while no catheters were used in 109 (40.7%) patients after URS.

Radiologic outcome on PODs 1 and 10

Of 182 patients with perioperative complete stone fragmentation, 163 were completely stone free, while fragments were observed on the KUB radiograph in 19 patients on POD 1 (Fig. 1). Of these 19 patients, six had fragments, and 13 were stone free on POD 10, determined by plain abdominal radiography. Of these 13 patients, however, obstruction was encountered in one patient who complained of persisting pain. URS determined that the obstruction was a distal ureteral stricture. The stricture was managed successfully by balloon dilatation in this patient, and his postoperative course was uneventful.

Of 75 patients who had partial fragmentation, 54 were stone free, while fragments were observed on KUB radiograph in 21 patients on POD 1 (Fig. 1). Of these 21 patients with fragments, nine still had fragments while 12 were stone free on POD 10.

Radiologic outcome in postoperative month 3

A total of 224 patients had IVU, 154 had ultrasonography, and 11 had noncontrast CT in the third postoperative month.

In 15 patients from two groups (complete fragmentation and partial fragmentation) with fragments at POD 10 assessed by KUB radiography, URS was again performed in eight, and radiologic follow-up with high fluid intake was offered to seven patients (Fig. 1). As assessed by IVU, seven of the eight patients who again underwent URS were stone free; in the remaining patient, IVU revealed retained stone fragments and obstruction, although the patient had no postoperative symptoms. In this patient, the condition was called silent obstruction. URS

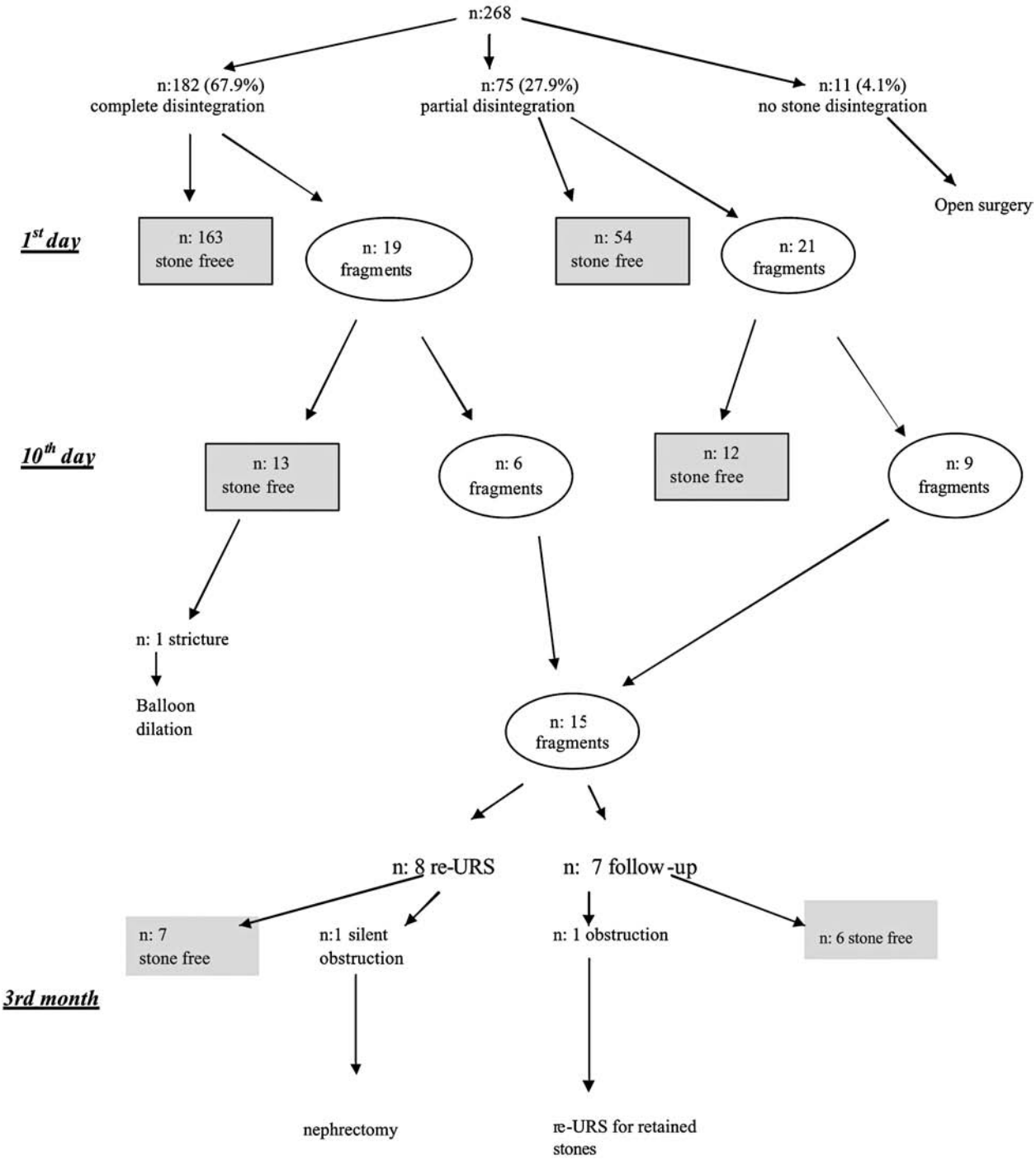

FIG. 1. Postoperative results of 268 patients who underwent ureteroscopy.

was performed, but it was unsuccessful because of severe ureteral stricture formation, and a percutaneous nephrostomy was placed. The nephrostomy tube was taken out because of a decrease in urine from the tube, and renal scintigraphy was performed. The patient finally underwent nephrectomy because of loss of renal function.

Of 7 patients undergoing radiologic follow-up, IVU determined that six were stone free at postoperative month 3; obstruction, observed in one patient because of retained stones, was managed by URS (Fig. 1). The obstruction disappeared during follow-up.

Results of radiologic surveillance

During follow-up, complete stone clearance was achieved in 256 (95.5%) patients at postoperative month 3. Open surgery

was performed in 11 (4.1%) patients for whom the procedures failed. In one patient who underwent nephrectomy during follow-up, URS was considered unsuccessful because of ureteral stricture formation. After a mean follow-up of 27.4 ± 13.7 (range 12–58) months, no additional long-term problem was diagnosed by annual radiologic surveillance studies.

Overall clinical outcome

Flank pain was accepted as a criterion for symptoms after URS. A total of 228 patients were asymptomatic, while 40 (14.9%) patients complained of symptoms after URS (Fig. 2). At the third postoperative month, IVU was performed. Two (5%) of the 40 symptomatic patients had obstruction caused by distal ureteral stricture (n = 1) and residual stone fragments (n = 1). Symptoms were related to residual ureteral stone fragments in 32 (80%) patients and edema of the ureteral orifice in eight (20%) patients. As mentioned, one (0.4%) patient in the asymptomatic group had silent obstruction at postoperative month 3 follow-up. The cause of obstruction was found to be distal ureteral stricture and coexistence of fragmented residual stones.

Interpretation of overall results

As shown on Fig. 1, none of patients determined to be stone free on POD 1 by plain abdominal radiography experienced long-term sequelae (i.e., obstruction, stricture formation). Symptomatic obstruction was observed in two (0.7%) patients during follow-up because of residual stones (n = 1) and stricture formation (n = 1), while silent obstruction was observed in one (0.3%) patient with renal function loss. All three patients were in the subgroup with residual fragments on POD 1 as determined by abdominal radiography (Fig. 1). In addition, preoperative radiologic findings revealed moderate to severe hydronephrosis in the three patients who experienced postoperative obstruction.

DISCUSSION

URS has become the most commonly used method for ureteral stone manipulation and extraction. Because of improvements in the instruments and accessories, URS has become safer and more effective.[5,6] Nevertheless, because of the concern for ureteral stricture development and subsequent renal deterioration, many urologists order functional radiographic studies.[9]

Harmon and associates[2] compared a recent cohort of patients undergoing URS with a group undergoing URS in the 1980s and showed an increase in the stone extraction success rate from 89% in the 1980s to 95% in 1992, with a success rate of 97% for distal stones in 1992. Diagnostic studies improved even more: from 73% to 98% success. In addition, only one stricture was detected, despite a 67% radiologic follow-up rate.[2] This is similar to the high success rate of 90% and low stricture rate of 1.6% seen in another recent study.[5] The average radiologic follow-up rate after URS in several recent studies was 65%, a number that vastly exceeds the number of patients experiencing postoperative pain in these reviews.[5]

Although the indications for URS are multiple, the guidelines for follow-up are few. To our knowledge, there are four studies questioning the need for routine radiologic surveillance after asymptomatic URS in the English literature, and only one of them advocates routine postoperative imaging after URS,[7] while the other three do not.[8–10]

Karod and colleagues[8] performed a retrospective medical record review of 183 patients who had undergone URS between 1989 and 1993 and 131 who had undergone postoperative radiologic studies that could diagnose ureteral obstruction. Of these patients, 110 (84%) were asymptomatic after the procedure, and radiologic procedures capable of displaying obstruction were performed at a median of 60 days after URS. Obstruction was not seen in any of these asymptomatic patients at the time of the routine follow-up radiologic procedure.[8] Of the

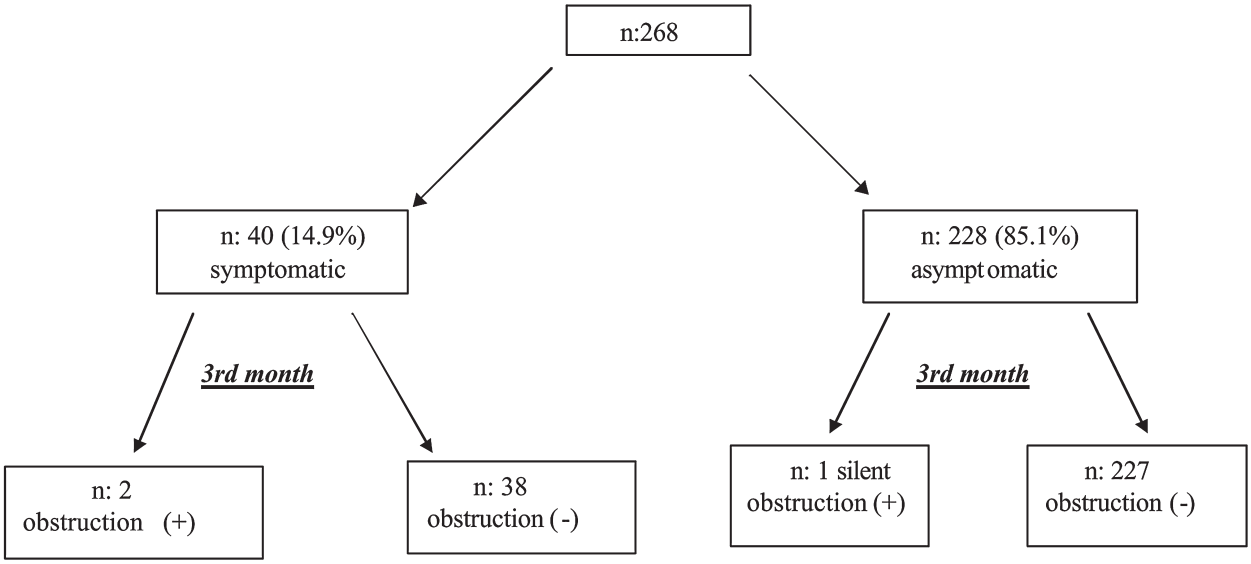

FIG. 2. Postoperative clinical assessment of patients.

21 (16%) patients who experienced flank pain subsequent to URS, 13 were found to have ureteral obstruction secondary to ureteral calculus. One patient (1/131 or 0.8%) was found to have a ureteral stricture, which occurred after a full-thickness ureteral injury. The investigators concluded that routine radiologic studies are not necessary in surveillance for obstruction in the asymptomatic post-URS patient, because obstruction should become evident with the onset of flank pain.[8]

In another study by Bugg and coworkers,[9] functional imaging studies were recommended for patients who presented with obstruction and pain after URS. These investigators concluded that a single plain radiograph might be sufficient for those with no obstruction and pain.

Weizer and associates,[7] however, determined the incidence of postoperative silent obstruction at their institution after reviewing the charts of 320 patients who had undergone 459 URS procedures for renal or ureteral calculi in a 3-year period. Complete follow-up with imaging was available for 241 (75%) patients. Mean follow-up was 5.4 months. Of the 241 patients, 30 (12.3%) had obstruction postoperatively. The cause was residual stone in 25(83.3%), stricture in three (10%), edema of the ureteral orifice in one (3.3%), and a retained encrusted stent in one (3.3%).

Postoperatively, obstruction correlated with postoperative pain in 23 (76.7%) of the 30 patients. Pain was present postoperatively in 30 (14%) of the 211 patients without evidence of ureteral obstruction. However, silent obstruction developed in seven (2%) patients. More importantly, one of these patients with silent obstruction ultimately received hemodialysis for renal failure. The investigators defined silent obstruction as radiographic evidence of obstruction without concurrent pain and concluded that silent obstruction remains a potentially significant complication after stone management. They recommended IVU, spiral CT, or ultrasonography within 3 months after routine URS stone management to avoid the potential complications of unrecognized ureteral obstruction.[7]

More recently, Beiko and coworkers[10] published their experience with upper tract imaging after ureteroscopic holmium:YAG laser lithotripsy. Although they report an evidence of urinary tract obstruction in six (8%) patients, they emphasize that routine postoperative upper tract imaging is not necessary in all patients undergoing uncomplicated ureteroscopic holmium:YAG laser lithotripsy. The investigators observed silent obstruction in 4.4% of their patients, and concluded that preoperative and preoperative findings that predicted potential risk for ureteral stricture formation mandated postoperative radiologic surveillance.

Our results also support close radiologic follow-up of a selected group of patients with preoperative severe hydronephrosis and retained fragments on POD 1.

In their study, Beiko and colleagues[10] recommended guidelines for imaging after URS. Preoperative factors indicating postoperative radiologic imaging included the presence of chronic stone impaction, complete ureteral obstruction, diminished renal function, history of ipsilateral ureteral stricture, secondary URS, and radiolucent stones. Significant ureteral edema, stone impaction, incomplete stone fragmentation, changes suspicious for stricture, ureteral perforation, and need for ureteral balloon dilation were intraoperative findings that indicate imaging after URS. Postoperative symptoms, such as ipsilateral flank pain and elevated body temperature (>38.5°C [101.3°F]), were indications for postoperative imaging.[10]

In addition to these guidelines, our results indicate that proximal migration of stone fragments, a relatively frequent complication of pneumatic lithotripsy, as well as presence of residual fragments seen on KUB radiography on POD 1 are other factors that indicate the need for postoperative radiologic surveillance.

In the present study, the rate of post-URS obstruction detected by radiologic studies was 1.1% (n = 3). In two patients, this problem was attributed to stricture formation and in one patient to residual stones. All but one of these patients complained of flank pain at the time of the radiologic studies. The other patient had no signs of obstruction and was said to have silent obstruction. Conversely, none of the completely stone-free patients who were asymptomatic at the time of radiologic examination showed any sign of obstruction. Furthermore, annual radiologic studies did not reveal any additional problems during long-term follow-up. Therefore, we do not recommend routine radiologic imaging for patients who are asymptomatic postoperatively.

Semirigid ureteroscopes (8F, 10F) and a pneumatic lithotriptor were used in the present study. Perioperative minor complications were observed in 28 (11%) patients in our series, which was consistent with previously published series.[5,11–18] The use of semirigid ureteroscopes for the management of stones above the iliac crest and the exclusive use of pneumatic lithotriptors in the era of laser technology is, of course, debatable.

The number of patients experiencing long-term sequelae (i.e., obstruction, stricture formation) in our series was small (1.1%) and did not allow us to statistically assess the impact of procedural factors, such as duration of procedure, occurrence of preoperative minor complications, use of ureteral stents, need for balloon dilation, diameter of ureteroscope used, and presence of preoperative hydronephrosis, on the long-term outcome.

With the use of small-caliber ureteroscopes, the rate of strictures reported in the literature has decreased to 2% or lower.[17–21] Although it is well known that preoperative complications such as ureteral tears or perforations are risk factors for long-term sequelae, previous studies suggest that other factors mentioned above do not have a significant impact on the outcome.[20,21]

As shown in a recent meta-analysis, there is a lack of standardization of the definition of uncomplicated URS.[22] In a randomized study to identify indications for placement of ureteral stents after URS stone removal, Denstedt and associates[23] defined uncomplicated URS as no evidence of perforation or lack of clinically important ureteral wall edema. Damaino and colleagues[24] proposed an endoscopic grading system of ureteric trauma and edema, which has not been validated, to our knowledge, on a scale of 0 (mild) to 2 (severe).

In our opinion, the stone-free status must also be considered in defining uncomplicated URS in addition to intraoperative findings and complications, because none of the patients rendered stone free (as assessed by KUB radiography on POD 1) experienced any long-term sequelae in the present study. Symptomatic obstruction (n = 2) and silent obstruction (n = 1) were observed in the subgroup of patients with residual fragments on POD 1.

CONCLUSION

Our results indicate that KUB radiography is mandatory on postoperative day 1 after uncomplicated URS stone removal. This simple radiologic imaging seems to be sufficient if the patient is rendered stone free and the postoperative course is without symptoms. A radiologic work-up with noncontrast spiral CT, which has proved to be more efficient in the documentation of residual stones, may be more beneficial at this stage, but this will increase cost.[25,26] Close radiological surveillance is indicated, however, for patients with residual fragments, postoperative symptoms, and preoperative findings that predict potential risk for stricture formation, and for those who experience intraoperative complications.

REFERENCES

1. Jeromin L, Sosnowski M. Ureteroscopy in the treatment of ureteral stones: Over 10 years' experience. Eur Urol 1998;34:344–349.
2. Harmon WJ, Sershon PD, Blute ML, Patterson DE, Segura JW. Ureteroscopy: Current practice and long-term complications. J Urol 1997;157:28–32.
3. Mohan-Pillai K, Keeley FX Jr, Moussa SA, Smith G, Tolley DA. Endourological management of severely encrusted ureteral stents. J Endourol 1999;13:377–379.
4. Erhard M, Salwen J, Bagley DH. Ureteroscopic removal of mid and proximal ureteral calculi. J Urol 1996;155:38–42.
5. Francesca F, Scattoni V, Nava L, Pompa P, Grasso M, Rigatti P. Failures and complications of transurethral ureteroscopy in 297 cases: Conventional rigid instruments vs. small caliber semirigid ureteroscopes. Eur Urol 1995;28:112–115.
6. Lingeman JE, Lifhitz DA, Evan AP. Surgical management of urinary lithiasis. In: Walsh PC, Retik AB, Vaughan ED, Wein AJ, eds. Campbell's Urology. Philadelphia: WB Saunders, 2002, pp 3361–3451.
7. Weizer AZ, Auge BK, Silverstein AD, et al. Routine postoperative imaging is important after ureteroscopic stone manipulation. J Urol 2002;168:46–50.
8. Karod JW, Danella J, Mowad JJ. Routine radiologic surveillance for obstruction is not required in asymptomatic patients after ureteroscopy. J Endourol 1999;13:433–436.
9. Bugg CE Jr, El-Galley R, Kenney PJ, Burns JR. Follow-up functional radiographic studies are not mandatory for all patients after ureteroscopy. Urology 2002;59:662–667.
10. Beiko DT, Beasley KA, Koka PK, Watterson JD, Nott LN, Denstedt JD, Razvi H. Upper tract imaging after ureteroscopic holmium:YAG laser lithotripsy: When is it necessary? Can J Urol 2003;10:2062–2067.
11. Aridogan IA, Zeren S, Bayazit Y, Soyupak B, Doran S. Complications of pneumatic ureterolithotripsy in the early postoperative period. J Endourol 2005;19:50–53.
12. Butler MR, Power RE, Thornhill JA, Ahmad I, McLornan I, McDermott T, Grainger R. An audit of 2273 ureteroscopies—a focus on intra-operative complications to justify proactive management of ureteric calculi. Surgeon 2004;2:42–46.
13. Du Fossé W, Billiet I, Mattelaer J. Ureteroscopic treatment of ureteric lithiasis. Analysis of 354 urs procedures in a community hospital. Acta Urol Belg 1998;66:33–40.
14. Puppo P, Ricciotti G, Bozzo W, Introini C. Primary endoscopic treatment of ureteric calculi. A review of 378 cases. Eur Urol 1999;36:48–52.
15. Schuster TG, Hollenbeck BK, Faerber GJ, Wolf JS Jr. Complications of ureteroscopy: Analysis of predictive factors. J Urol 2001; 166:538–540.
16. Sözen S, Küpeli B, Tunc L, Senocak C, Alkibay T, Karaoglan U, Bozkirli I. Management of ureteral stones with pneumatic lithotripsy: Report of 500 patients. J Endourol 2003;17:721–724.
17. Strohmaier WL, Schubert G, Rosenkranz T, Weigl A. Comparison of extracorporeal shock wave lithotripsy and ureteroscopy in the treatment of ureteral calculi: A prospective study. Eur Urol 1999; 36:376–379.
18. Yaycioglu O, Guvel S, Kilinc F, Egilmez T, Ozkardes H. Results with 7.5F versus 10F rigid ureteroscopes in treatment of ureteral calculi. Urology 2004;64:643–647.
19. Roberts WW, Cadeddu JA, Micali S, Kavoussi LR, Moore RG. Ureteral stricture formation after removal of impacted calculi. J Urol 1998;159:723–726.
20. Stackl W, Marberger M. Late sequelae of the management of ureteral calculi with the ureterorenoscope. J Urol 1986;136:386–389.
21. Grasso M. Ureteropyeloscopic treatment of ureteral and intrarenal calculi. Urol Clin North Am 2000;27:623–631.
22. Nabi G, Cook J, N'Dow J, McClinton S. Outcomes of stenting after uncomplicated ureteroscopy: Systematic review and meta-analysis. BMJ 2007;334:572–578.
23. Denstedt JD, Wollin TA, Sofer M, Nott L, Weir M, D'A Honey RJ. A prospective randomized controlled trial comparing nonstented versus stented ureteroscopic lithotripsy. J Urol 2001;165:1419–1422.
24. Damiano R, Autorino R, Esposito C, Cantiello F, Sacco R, de Sio M, D'Armiento M. Stent positioning after ureteroscopy for urinary calculi: The question is still open. Eur Urol. 2004;46:381–388.
25. Pearle MS, Watamull LM, Mullican MA. Sensitivity of noncontrast helical computerized tomography and plain film radiography compared to flexible nephroscopy for detecting residual fragments after percutaneous nephrostolithotomy. J Urol 1999;162:23–26.
26. Küpeli B, Gürocak S, Tunc L, Senocak C, Karaoglan U, Bozkirli I..Value of ultrasonography and helical computed tomography in the diagnosis of stone-free patients after extracorporeal shock wave lithotripsy (USG and helical CT after SWL). Int Urol Nephrol 2005;37:225–230.

Address reprint requests to:
Ahmet Tefekli, M.D.
Haseki Teaching and Research Hospital
Millet Street, Haseki
34800 Istanbul, Turkey

E-mail: atefekli@yahoo.com

ABBREVIATIONS USED

CT = computed tomography; IVU = intravenous urography; KUB = kidneys, ureters, and bladder; SWL = shockwave lithotripsy; YAG = yttrium aluminum garnet.